

DROP COLORS

Dilating red

Phenylephrine, tropicamide, atropine, cyclopentolate, cyclomydril



Carbonic anhydrase inhibitors Orange

brinzolamide (Azopt), Dorzolamide (Trusopt)



Beta blockers yellow/light blue

Timolol (Timoptic), levobunolol (Betagan) - yellow



Betaxolol (Betoptic) – light blue top

Prostaglandin analogue Turquoise

Latanoprost (Xalatan), travoprost (Travatan), bimatoprost (Lumigan)



Combo drops with timolol Blue

Dorzolamide-timolol (Cosopt), brimonidine-timolol (Combigan)



Alpha agonist – Purple

Brominidine (Alphagan)



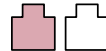
Antibiotics Tan/Beige

Ofloxacin (Ocuflox), ciprofloxacin (Ciloxan), moxifloxacin (Vigamox, Moxeza), gatifloxacin (Zymar, Zymaxid), besifloxacin (Besivance)



Steroid Pink/White

Prednisolone acetate (Pred Forte/Pred Mild), fluoromethalone (FML), rimexolone (Vexol), loteprednol (Lotemax), difluprednate (Durezol)



Topical NSAID Grey

Ketorolac (acular, acuvail), diclofenac (Voltaren)



Topical anesthetics White

Proparacaine, tetracaine



Generic/OTC Varies

Often do not follow the color guides!



HPI KEY QUESTIONS

Don't forget to say here for ____

Floaters and Flashing Lights

Ask everyone, new or worsening?

Transient Vision Loss

Migraine spasm in young, microemboli in elderly

Curtain of darkness → ischemic event or retinal detachment

Blurry

Always? Worsens when reading or watching TV? (Dry bc ↓ blinking) glare? Worse at night? DM?

Red/Painful

Scratchy? Aching? Photophobia? Discharge? (describe)

Chronic pruritis/Tearing

Allergies? Blepharitis? Laterality?

Headaches & Scalp Tenderness

Temporal GCA? (jaw claud, polymyalgia, WL, night sweats?)

Ask PMH, meds, eye probs, surgery, lasers, Fhx, etc

TECH WALK IN

Ask what's most helpful for resident

Can use dilating time for more history if needed but get CC and basic history

Ask med adherence including last time used drops, red flags for everyone (pain, redness, flash, dots, photophobia, floaters), falls

Vision

Once getting harder to see, pinhole

Pupils

Often done in the room with resident but swinging light to check for APD.
2-4 light, 4-8mm dark

Pressure

Ensure clean or cap used. Select correct method with drop down.
Tonopen, applanation etc
Normal is 11-21 in adults

Cabinet white top with tissue to numb

Red if dilating, ask 1st

Clean slit lamp

Fluoro strip in inferior fornix, less blotchy than the drops

Room light on slit lamp arm

Patients may go to subway, help walk patients to areas

MISC